

## Autonomously Controlled Magnetic Flexible Endoscope for Colon Exploration



Piotr R. Slawinski,<sup>1</sup> Addisu Z. Taddese,<sup>1</sup> Kyle B. Musto,<sup>1</sup> Shabnam Sarker,<sup>2</sup> Pietro Valdastrì,<sup>3</sup> and Keith L. Obstein<sup>1,2</sup>

<sup>1</sup>Department of Mechanical Engineering, <sup>2</sup>Division of Gastroenterology, Vanderbilt University, Nashville, Tennessee, and <sup>3</sup>School of Electronic and Electrical Engineering, University of Leeds, Leeds, United Kingdom

This article has an accompanying continuing medical education activity, also eligible for MOC credit, on page e22. Learning Objective: Upon completion of this CME activity, successful learners will be able to identify limitations of current technology for gastrointestinal endoscopy and assess the capability of magnets to overcome these limitations.



Scan the quick response (QR) code to the left with your mobile device to watch this article's video abstract and others. Don't have a QR code reader? Get one by searching 'QR Scanner' in your mobile device's app store.

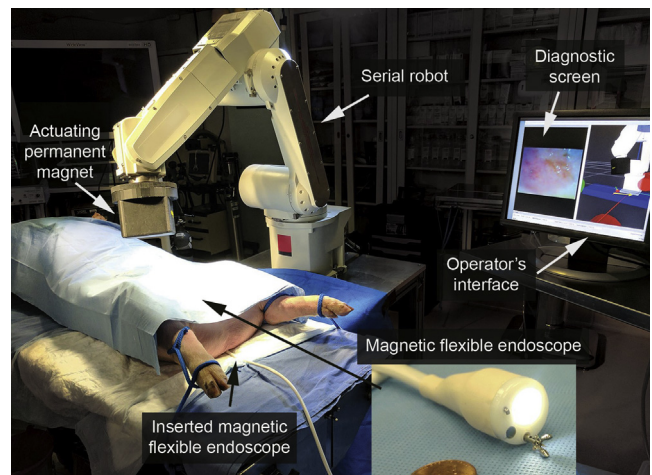
Traditional flexible endoscopes, which have been in use since the 1950s, rely on rear-push mechanical actuation to advance through the gastrointestinal tract. This necessitates a semirigid insertion tube to prevent buckling that may induce patient discomfort or trauma owing to tissue stress.<sup>1,2</sup> To overcome this limitation, magnetic fields have been used for endoscope actuation. Unfortunately, manual operation of magnetic actuation is not intuitive and, therefore, computer assistance has been shown to be beneficial.<sup>3</sup> The use of computers and robotics facilitates autonomy, which may be used to assist the operator during repetitive or complex maneuvers through relief of cognitive burden and potential learning curve reduction.

In our academic laboratory, we have developed a highly compliant magnetic flexible endoscope (MFE) platform (with diagnostic and therapeutic capability) that relies on actuation using an actuating permanent magnet (APM) manipulated by a robot that is external to the patient; thus, it does not require push actuation. Using proprioceptive sensing and software algorithms, we are able to control MFE motion and enact autonomous function.

Within endoscopy, colonoscopy is ripe for autonomous control owing to the repetitive nature of some maneuvers and the skill/experience necessary to achieve excellent technique. We focus our demonstration of autonomy on retroflexion because it is a common endoscopic maneuver that is skill intensive, repetitive, and technically challenging when using magnetic actuation. The ability to safely retroflex the MFE in any area of the colon may potentially increase polyp detection and reduce the incidence of colorectal cancer.<sup>4</sup>

Our team has developed an autonomous control algorithm for MFE retroflexion. We conducted 30 autonomous

retroflexions in vivo in a 40-kg female Yorkshire-Landrace cross swine (Supplementary Material: Retroflexion study design). All of the autonomous retroflexion maneuvers were successful (100%; n = 30) with a mean maneuver time of  $11.3 \pm 2.4$  seconds. The visible difference in trajectories and difference in APM position respective to the starting point indicate that the APM did not follow a precomputed trajectory, but was instead autonomously reacting to external input, in this case the MFE's motion (Video Clip 1). All of the trials in this study were completed without tissue

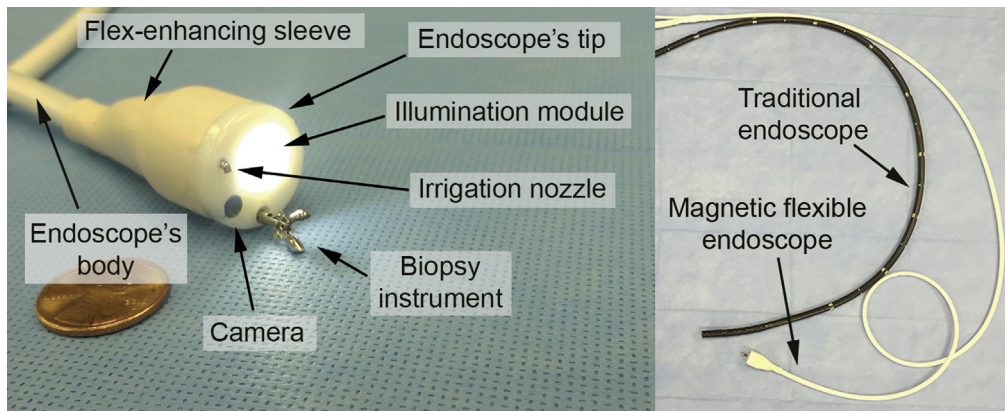


**Figure 1.** The magnetic flexible endoscope platform consists of a magnet-embedded custom endoscope, a serial robot with an actuating permanent magnet mounted at its end-effector, and control software. The system is shown during an in vivo trial.

**Abbreviation used in this paper:** APM, actuating permanent magnet; MFE, magnetic flexible endoscope.

Most current article

© 2018 by the AGA Institute  
0016-5085/\$36.00  
<https://doi.org/10.1053/j.gastro.2018.02.037>



**Figure 2.** The compliant magnetic flexible endoscope contains a camera, illumination module, therapeutic channel, an irrigation channel, and a flexible sleeve joint that joins the endoscope's tip to its body (left).

perforation or trauma (gross or microscopic), or premature animal demise during the trial. The study was approved by the local Institutional Animal Care and Use Committee.

In addition, the feasibility of the diagnostic capabilities of the MFE was assessed through a series of preliminary experiments on lesion detection and lesion-targeting (Supplementary Material: Lesion Detection and Targeting Study Design). The mean lesion detection miss rate for the MFE was 21.7% (completion time, 575 s) compared with a miss rate of 5% (completion time, 257 s) with the traditional endoscope ( $P = .17$ ). For the lesion targeting experiments, all lesions were successfully “tagged” with biopsy forceps using the MFE and the traditional endoscope (time of 251 s vs 32 s;  $P < .01$ ). Despite the differences in time between the MFE and traditional endoscope, likely impacted by endoscopist familiarity with traditional endoscopy, the low polyp miss rate and ability to circumferentially examine the colon lumen suggest promise for continued development and refinement of the MFE.

## Description of Technology

The MFE system (Figure 1) consists of a flexible endoscope with a magnet-embedded tip, an APM external to the patient that is manipulated by a robot, and a software control system that is described in detail in Slawinski et al.<sup>5</sup> The MFE (Figure 2) maintains functionality of a traditional endoscope (ie, therapeutic channel, illumination, viewing, irrigation, suction, lens cleansing, and insufflation) and contains proprioceptive sensors that facilitate magnetic interaction estimation harnessed for MFE retroflexion. Knowledge of magnetic field properties allows for precise device movement all while maintaining an applied tissue stress of no more than 0.25 bar, or 12 times less pressure than is necessary to induce tissue damage.<sup>5,6</sup>

## Video Description

The video presents an overall description of the MFE platform and functions followed by demonstration of

in vivo autonomous retroflexion in real time. The robot arm with the APM is shown in the upper right of the screen during the demonstration and the corresponding footage of the MFE is shown in the frame below, where perspective footage is obtained via an auxiliary endoscope. Furthermore, we demonstrate unique MFE trajectories during retroflexion—a product of the use of autonomy, the use of biopsy forceps during MFE retroflexion, as well as the in vivo use of therapeutic tools as operated from the MFE.

## Take Home Message

Our team has demonstrated the first use of in vivo autonomous control for the completion of an endoscopic maneuver in a reliable, efficient, and safe manner. This is also the first study to demonstrate closed-loop magnetic control of a device in vivo and autonomous maneuvering of an endoscope that has the clinical capability of a traditional flexible endoscope.

We expect the cost of the MFE to be approximately \$1000 USD with a one-time cost of \$40,000 USD for the actuating robot. Although we have developed the technology for use in the colon, we anticipate that the platform, once further miniaturized, can be used in the upper gastrointestinal tract and, in general, other areas of the body where there is physical space for maneuvering. In summary, our findings suggest promise in the use of autonomy to assist in endoscopic tasks and in magnetic actuation of endoscopic devices/instruments.

## Supplementary Material

Note: To access the supplementary material accompanying this article, visit the online version of *Gastroenterology* at [www.gastrojournal.org](http://www.gastrojournal.org), and at <https://doi.org/10.1053/j.gastro.2018.02.037>.

## References

1. Obstein KL, Valdastrri PR. Advanced endoscopic technologies for colorectal cancer screening. *World J Gastroenterol* 2013;19:431–439.

2. Sliker LJ, Ciuti G. Flexible and capsule endoscopy for screening, diagnosis and treatment. *Exp Rev Med Devices* 2014;11:649–666.
3. Ciuti G, Donlin R, Valdastrì P, et al. Robotic versus manual control in magnetic steering of an endoscopic capsule. *Endoscopy* 2010;42:148–152.
4. Cohen J, Grunwald D, Grossberg LB, et al. The effect of right colon retroflexion on adenoma detection: a systematic review and meta-analysis. *J Clin Gastroenterol* 2017;51:818–824.
5. Slawinski PR, Taddese AZ, Musto KB, et al. Autonomous retroflexion of a magnetic flexible endoscope. *IEEE Robot Autom Lett* 2017;2:1352–1359.
6. Moshkowitz M, Hirsch Y, Carmel I, et al. A novel device for rapid cleaning of poorly prepared colons. *Endoscopy* 2010;42:834–836.

---

#### Reprint requests

Address requests for reprints to: Keith Obstein, MD, MPH, FASGE, 1301 Medical Center Drive, Suite 1660 The Vanderbilt Clinic, Nashville, TN 37232. e-mail: [keith.obstein@vanderbilt.edu](mailto:keith.obstein@vanderbilt.edu).

#### Conflicts of interest

The authors have made the following disclosures: Piotr R. Slawinski, Addisu Z. Taddese, Pietro Valdastrì, and Keith L. Obstein have submitted an invention disclosure to Vanderbilt University. Kyle B. Musto and Shabnam Sarker have nothing to disclose. Shabnam Sarker, Piotr R. Slawinski, Addisu Z. Taddese, Kyle B. Musto, Pietro Valdastrì, and Keith L. Obstein have no conflicts of interest.

#### Funding

This research was supported by the National Institute of Biomedical Imaging and Bioengineering, USA of the National Institutes of Health under award no. R01EB018992, by the National Science Foundation, USA under grant no. CNS-1239355 and no. IIS-1453129, by the National Science Foundation Graduate Research Fellowship Program under grant no. 1445197, by the Royal Society, UK, and by the Engineering and Physical Sciences Research Council, UK. Any opinions, findings, conclusions, or recommendations expressed in this material are those of the authors and do not necessarily reflect the views of the National Institutes of Health, the National Science Foundation, the Royal Society, or the Engineering and Physical Sciences Research Council.

## Supplementary Material

### *Retroflexion Study Design*

A standard colonoscope (Olympus, CF-Q160L, Tokyo, Japan) was initially inserted into the anus of an anesthetized swine and advanced proximally until further proximal advancement of the endoscope was not possible owing to the swine's spiral colon. The colonoscope was then withdrawn to a distance of 25 cm from the anus and retroflexion was performed in this location. The colonoscope was then kept in this location while the magnetic flexible endoscope (MFE) was inserted into the anus of the swine. The MFE was then advanced under magnetic control to 25 cm from the anus, where retroflexion trials were performed. Each experiment was conducted under full autonomy; the only human input was the pushing of a keyboard button on a personal computer to initiate the algorithm (a functionality that can be easily integrated into the operator's handle for the system). A total of 30 independent autonomous retroflexion maneuvers were performed.

### **Lesion Detection and Targeting Study Design**

As in Laborde et al,<sup>1</sup> a series of polyps (size <10 mm) were placed in a colon phantom in 1 of 5 location scenarios.

The MFE and traditional endoscope were used for visual inspection of the colon upon withdrawal. The location scenario and endoscope used for the scenario were randomized between each trial. Each scenario was performed twice for a total of 10 inspection trials.

For lesion targeting, the colon phantom (Kyoto Kagaku, Kyoto, Japan) was prepared so that 8 polyps (<10 mm in size) were placed along the colon circumferentially, 180° apart per distance pair, that rotated every 2 cm when moving in a retrograde manner with the endoscope (0°, 45°, 90°, 135°, 180°, 225°, 270°, and 315°). The MFE and the traditional endoscope were then used to identify and “tag” the polyp using a cold biopsy forceps that was advanced through the therapeutic channel of the endoscope. A “tag” was considered successful when the cold biopsy forceps was open and touched the polyp for removal. A total of 10 trials were performed (MFE n = 5; traditional endoscope n = 5).

### **Reference**

1. Laborde CJ, Bell CS, Slaughter JC, et al. Evaluation of a novel tablet application for improvement in colonoscopy training and mentoring (with video). *Gastrointest Endosc* 2017;85:559–565.